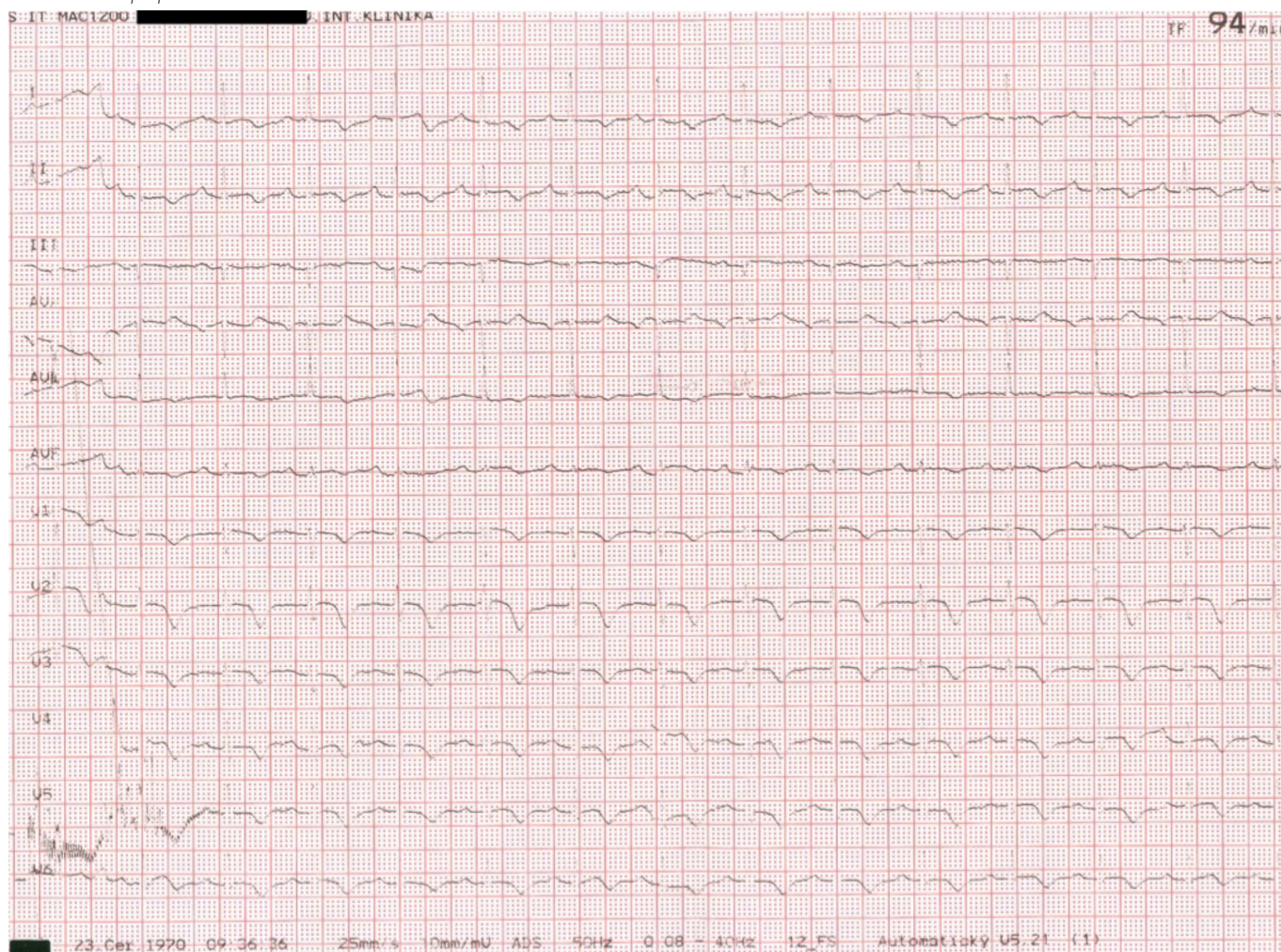


Obr. 3 4 EKG po preklade z NÚSCH



## Záver

Stresová („takotsubo“) KMP je relatívne raritná diagnóza, na ktorú je potrebné myslieť predovšetkým u osôb ženského pohlavia v postmenopauzálnom veku so stenokardiami

a anamnézou emocionálneho alebo fyzického stresového podnetu. Aj keď jej priebeh i prognóza sú zväčša priaznivé, je potrebné mať na pamäti, že najmä u rizikovejších pacientov sa môžu vyvinúť komplikácie od menej závažných až po úmrtie.

## LITERATÚRA

- Sato H Tako-tsubo-like left ventricular dysfunction due to multivessel coronary spasm. In: Kodama K, Haze K, Hori M (eds.) Clinical Aspect of Myocardial Injury: From Ischemia to Heart Failure. Tokyo: Kagakuhyoronsha Publishing Co 1990, 56–64.
- Pavin D, Le Breton H, Daubert C Human stress cardiomyopathy mimicking acute myocardial syndrome. *Heart* 1997; 78: 509–511.
- Sharkey SW, Shear W, Hodges M et al. Reversible myocardial contraction abnormalities in patients with an acute noncardiac illness. *Chest* 1998; 114: 98–105.
- Dúbrava J Tranzitórna apikálna balónová dysfunkcia ľavej komory – syndróm imitujúci akútny infarkt myokardu. *Cardiol* 2005; 14: 92–96.
- Paleček T, Linhart A, Jansa P et al. Takotsubo kardiomyopatie: popis prípadu a prehľad literatúry. *Čas Lék Čes* 2005; 144: 406–408.
- Templin C, Ghadri JR, Diekmann J et al. Clinical features and outcomes of takotsubo (stress) cardiomyopathy. *N Engl J Med* 2015; 373: 929–938.
- Chams S, Sayegh SE, Hamdon M et al. Zumba-induced Takotsubo cardiomyopathy: a case report. *Journal of Medical Case Reports* 2018; 12: 160.
- Bybee KA, Kara T, Prasad A et al. Systematic review: transient left ventricular apical ballooning: a syndrome that mimics ST-segment elevation myocardial infarction. *Ann Intern Med* 2004; 141: 858–865.
- Suzuki H, Matsumoto Y, Kaneta T et al. Evidence for Brain Activation in Patients with Takotsubo Cardiomyopathy. *Circ J* 2014; 78: 256–258.
- Ghadri JG, Wittstein IS, Prasad A et al. International Expert Consensus Document on Takotsubo Syndrome (Part I): Clinical Characteristics, Diagnostic Criteria, and Pathophysiology. *European Heart Journal* 2018; 39: 2032–2046.
- Bill V, El-Battrawy I, Schramm K et al. Coincidental coronary artery disease impairs outcome in patients with takotsubo cardiomyopathy. *QJM: An International Journal of Medicine* 2017; 32: 483–488.
- Ghadri JR, Cammann VL, Jurisic S et al. A novel clinical score (InterTAK Diagnostic Score) to differentiate takotsubo syndrome from acute coronary syndrome: results from the International Takotsubo Registry. *Eur J of Heart Fail* 2017; 19: 1036–1042.
- Tamis-Holland JE, Jneid H, Reynolds HR, et al. Contemporary Diagnosis and Management of Patients With Myocardial Infarction in the Absence of Obstructive Coronary Artery Disease: A Scientific Statement From the American Heart Association. *Circulation* 2019; 139: e891–e908.
- Kubena P, Bohatá Š, Maňoušek J et al. Takotsubo kardiomyopatie, klinické zkušenosti s onemocněním a jednoletá prognóza pacientů. *Vnitř Lék* 2015; 61: 619–625.
- Fröhlich GM, Schoch B, Schmid F et al. Takotsubo cardiomyopathy has a unique cardiac biomarker profile: NT-proBNP/myoglobin and NT-proBNP/troponin T ratios for the differential diagnosis of acute coronary syndromes and stress induced cardiomyopathy. *Int J Cardiol* 2012; 154: 328–332.
- Nguyen TH, Neil CJ, Sverdlow AL et al. N-terminal pro-brain natriuretic protein levels in takotsubo cardiomyopathy. *Am J Cardiol* 2011; 108: 1316–1321.
- Lyon AL, Bossone E, Schneider B et al. Current state of knowledge on Takotsubo syndrome: a position statement from the task force on Takotsubo syndrome of the Heart Failure Association of the European Society of Cardiology. *European Journal of Heart Failure* 2016; 18: 8–27.
- Eitel I, Knobelsdorf-Brenkenhoff F, Bernhardt P et al. Clinical Characteristics and Cardiovascular Magnetic Resonance Findings in Stress (Takotsubo) Cardiomyopathy. *JAMA* 2011; 306: 277–286.